

See discussions, stats, and author profiles for this publication at: <https://www.researchgate.net/publication/51379750>

# Cleaner LASIK is possible

Article in *The Journal of the Louisiana State Medical Society: official organ of the Louisiana State Medical Society* · January 2007

Source: PubMed

---

CITATION

1

---

READS

538

3 authors:



Leon Lahaye

3 PUBLICATIONS 1 CITATION

SEE PROFILE



Herman Rieke

University of Louisiana at Lafayette

35 PUBLICATIONS 691 CITATIONS

SEE PROFILE



Fred Farshad

University of Louisiana at Lafayette

69 PUBLICATIONS 943 CITATIONS

SEE PROFILE

# Cleaner LASIK is Possible

L.C. LaHaye, MD; Herman Rieke, PhD; and Fred Farshad, PhD

LASIK (laser in situ keratomileusis) surgery is the most frequently performed refractive procedure for correcting nearsightedness, farsightedness, and astigmatism. Its popularity increased over the late 1990's, rapidly replacing Radial Keratotomy (RK). The LASIK operation and excimer laser surface ablation procedures gained the rapid acceptance of refractive physicians and patients over the RK procedure because of greater predictability, precision, safety, and stable vision.

In the mid 90's, when doctors first began performing LASIK, it was referred to implicitly as the "FLAP and ZAP" procedure. This of course was an overly confident misstatement as unfamiliar complications began to appear.

One of the ultimate goals in performing any surgical procedure is to minimize less than desirable outcomes arising from both infectious and non-infectious contaminants entering the surgical field. This is especially true of all corneal procedures, such as LASIK, where the normal mechanisms for fighting contaminations are diminished.

## LASIK STAGES I AND II

The following discussion of the two stages present an overview of complicating surgical and health issues in LASIK surgery. Stage I of the LASIK operation involves the automated mechanical or laser-performed keratotomy ("Flap") that presents the surgeon in theory with a closed, non-contaminated surgical incision. Most patients requesting refractive surgery are relatively young and healthy, thereby minimizing the possibility of having systemic diseases, which would impede surgical success. Such complications fall outside the discussion of standardized procedures that should result in a cleaner Stage II LASIK.

Stage II of the LASIK operation is much more dynamic and involves a multiplicity of procedures that requires consistency, standardization, and strict adherence to basic surgical principles and techniques to avoid less than desired outcomes. The excimer laser dose delivery is only one aspect of the more technically demanding Stage II. Stage II begins when the corneal flap is reflected (opening the incision) and is completed with the corneal flap returned and sealed in its original position (closure of the incision): **surgical incision exposure to surgical incision closure**. During this stage invasive solids and fluids can arise owing to the involuntary introduction of infectious organisms, epithelial cells, debris, oils, etc. into the stroma after the corneal flap is reflected back off the corneal surface. Manipulations of the epithelial surfaces, flap, flap bed, introduction

and extraneous use of instruments at the interface, flap folding, irrigation and cleansing of the surface, coupled with possible contaminations from the eyelashes, stromal bed tissue, tear ducts, proliferation and/or migration of epithelial cells, and the limbus throughout the second stage of the LASIK procedure may contribute to less than desirable outcomes.

Moreover, splatter from the ablation plume can partially mask the laser beam impairing the laser's efficiency and could create undesired outcomes that require future surgical correction. Excimer surgeons sometimes have observed the generated plume to carry large particles, which can drop out onto the surgical field creating additional contamination in the region of the incision. These particles also may adhere after splattering onto the laser's last optic resulting in irregular etching. Both events cause grief for the surgeon and patient and may require complex surgical intervention in an attempt to correct poor outcomes. Additionally, splatter, smoke, and large particles are possible health and safety issues for the surgeon, medical staff, and patient.

## STAGE II LASIK'S NINE PLUS SURGICAL FUNCTIONS

How was the LASIK surgical method improved to mitigate the above mentioned complications? This appears to be a difficult goal to achieve owing to the variability among surgeons' practice and skills. Before specifically

addressing this question, a review of the nine important operational functions that a surgeon has to handle in the second stage of LASIK is in order.

### Containment of the surgical field

The surgical field boundaries of the standard LASIK procedure include the patient's lid margins, lashes, cul-de-sac tissues, and surgical drape if used. These regions can be sources of contamination. It is known that the exposed corneal stroma has the potential to absorb and hold invasive fluids like a sponge. Buratto et al<sup>1</sup> and Pushker et al<sup>2</sup> pointed out that a reduction in the exposure of the corneal bed and flap tissues can reduce post-operative complications, including infectious keratitis and diffuse lamellar keratitis.

A cleaner LASIK procedure would require the downsizing as well as the containment of the surgical field in order to reduce exposure of the corneal bed and flap tissues to contamination and thereby reduce the possibility of infectious keratitis and diffuse lamellar keratitis.

### Fixation and control of eye movements

Fixation of the patient's eye is problematic in conventional LASIK surgery, and raises four main issues of concern. The first issue involves the standard procedure to use various surgical tools, which unfortunately do not downsize the surgical field nor provide for containment of the delicate and highly absorbent flap and stromal bed tissues. Figure 1 shows uncontrolled reflex eye movement during standard LASIK surgery that result in rubbing and direct contact of the exposed delicate corneal flap and flap bed tissues against the lid speculum, lid margins, lashes, and pooling fluids.

A second issue is the excimer laser beam's tracking: it has limitations because there will always be a critical delay between measurement alignment and delivery. Even with high tracking sampling rates at 4,000 times per second, time is needed to adjust the laser mechanics and optics to ensure proper energy

up to 19  $\mu\text{m}$ . Large eye movements can interfere with the tracker's ability to track properly causing a temporary shut down of the laser beam delivery.

A third issue is that most trackers do not actively track cyclo-rotation movements of the eye, which can contribute to inaccurate placement of the laser. This misalignment of the axis during laser delivery can result in poor visual outcomes with increased higher order aberrations and loss of best-corrected vision.

A fourth limitation is that trackers create a false sense of security causing some surgeons to take a back-seat approach to the laser delivery step of Stage II.

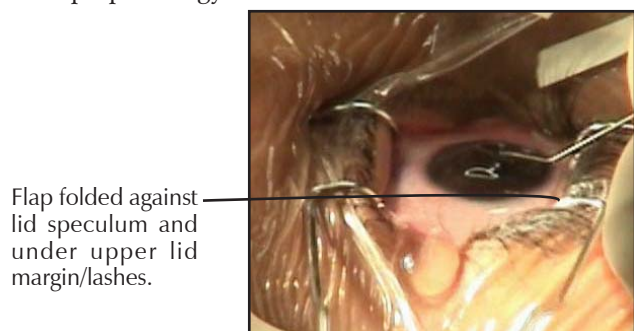
### Corneal flap management

In theory, after performing a keratotomy the surgeon is presented with a closed, non-contaminated corneal incision. The flap must be reflected to expose the underlying stromal bed that is the target to be corrected by removal of tissue, which reshapes the curvature of the cornea. Typically the flap is reflected open or sometimes folded in half, so-called taco technique, and then flayed either directly on the eye (nasal or temporal hinge), lid margin region (superior flap hinge), or on a surgical sponge or metal tool where it remains throughout the laser delivery. During this period the highly absorbent flap may be subjected to mechanical stress. The highly absorbent flap may be marinating in fluids and secretions that contain debris, oils, and other contaminants from direct contact with the conjunctiva, lid margins, and lashes. None of these methods provide for containment of the highly absorbent flap.

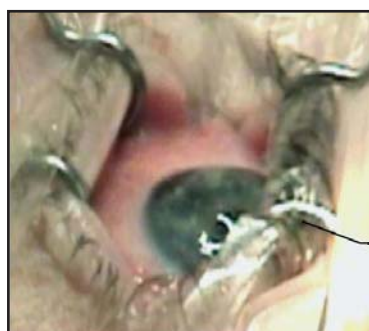Examples of these conditions are presented in Figure 2 illustrating the position of the corneal flap: (1) lying on a metallic speculum; (2) laid folded on patient's lid margin; and (3) on the lashes. A cleaner LASIK procedure would have to eliminate flap reflection uncertainties.

### Removal of flap-bed surface fluid/moisture

Surgeons must rely on a variety of techniques and devices to modify and



Flap folded against lid speculum and under upper lid margin/lashes.



Exposed flap/bed rolled under lid margin/speculum.

**Figure 1.** Patient's uncontrolled reflex eye movements can result in direct contact of the exposed delicate corneal flap and flap bed tissues against the lid speculum, lid margins, lashes, and pooling fluids during conventional LASIK.

delivery to the predetermined corneal target site. During a latency period of 10 milliseconds, the normal eye can move

adjust for dynamic changes relative to hydration variability on the target stromal tissue surface during laser pulse

# We Can Help You Measure Up To New Challenges



TAKING COURSES TO STAY ON THE CUTTING EDGE OF MEDICINE IS VITAL. Our Continuing Education Loans help you do just that. And you can pay only interest for up to two years! If you were to use a credit card, your minimum payment would be more than five times this amount. **Currently, the interest rate is 10.25% APR.\***

Applying is as easy as picking up the phone and using our Push Button Loans<sup>SM</sup> service, visiting the Web or speaking to a member service representative in person. For more information, give us a call.

**CAMPUS FEDERAL**  
BE A PART OF IT<sup>SM</sup>

888-769-8841 [www.campusfederal.org](http://www.campusfederal.org)

\*As of July 5, 2006, the current Annual Percentage Rate (APR) is 10.25%. This rate is variable and based on Wall Street Journal Prime plus 2%. Payments for the balance of the loan after the initial 24 months are based on a 24 month amortization at WSJ Prime plus 2%. At the current rate of interest, payments on a loan of \$3,500 would be \$29.90 per month initially. Assuming no change in the interest rate during amortization, monthly payments for the following 24 months would be \$161.95. Rates are variable and subject to change without notice. Minimum loan amount is \$1,000. Maximum loan amount is \$15,000. Normal credit criteria apply.

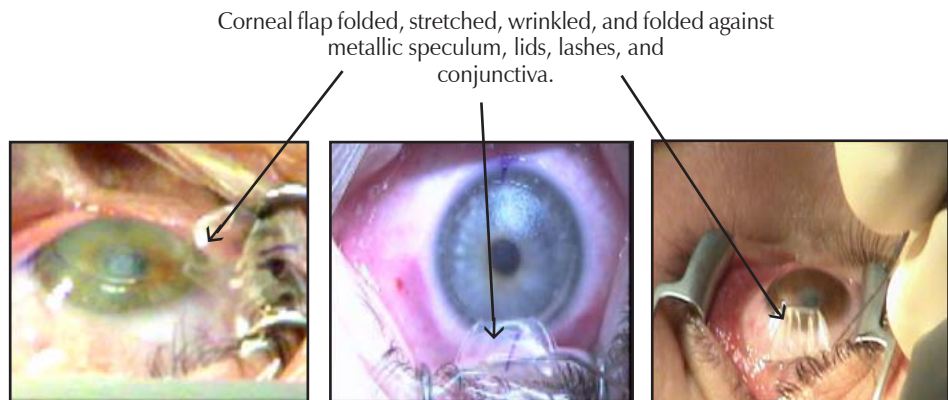


delivery. Stromal fluid can mask, ie diminish, the laser energy's ability to remove tissue, causing variations in ablation that can result in islands and under correction.<sup>4</sup> Standard procedures are to wipe the surface using a micro-sponge and/or to employ airflow to evaporate the excessive moisture from the stromal bed prior to and during ablation. Unfortunately, the micro-sponge leaves the stromal surface visibly grainy and rough. A dry sponge is rough and can create abrasions at the margins of the flap bed. Some conventional LASIK procedures use airflow through tubing, which may not be filtered or sterile, to the corneal surface to minimize uneven and changing hydration conditions, which could result in central islands or under corrections. A cleaner LASIK procedure will reduce the possibility of surgical enhancements or revisions due to corneal hydration variability during and prior to ablation.

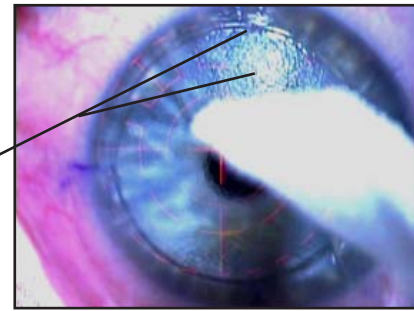
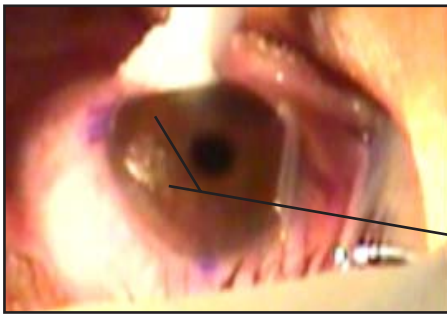
### Plume evacuation

Plume generated during LASIK surgery can present several potential troublesome operational outcomes and patient/surgeon health problems. Plume is created

when the excimer laser pulse strikes cornea water vapor and live and dead cellular debris located in the surgical field. The ablation process breaks the nitrogen peptide bonds in cellular proteins generating plume "smoke", which is an aerosol that can result in a beam blocking effect as the plume hangs over the ablating stromal bed blocking subsequent laser pulses. The plume composition includes water vapor, cellular and carbonized tissue, blood, and viruses in conjunction with benzene, hydrogen cyanide, toluene gases, formaldehyde, and polycyclic aromatic hydrocarbons. Droplets in the plume's tail were shown to be



**Figure 2.** Examples of the absorbent corneal flap placement on a metallic speculum, and/or the lid margin/lashes, or the conjunctiva typical of conventional LASIK.



Rough and grainy areas from use of sponge

**Figure 3.** The micro sponge used to wipe the surface leaves the stromal surface grainy and rough and can create micro abrasions at the margins of the flap bed, which may contribute to complications.

sufficiently numerous that collisions among them will lead to their coalescence creating larger droplets in the plume.<sup>5</sup> The complexities of plume formation and its rapid dynamic movements both vertical and laterally impose upon the surgeon problems that can present undesirable outcomes.

There is considerable variability in LASIK surgery in the way that excimer generated plume is managed. Standard LASIK plume management is based typically on the evacuation of the plume with large volume laser-integrated plume evacuation systems. Some do not provide for plume evacuation.

Any cleaner LASIK procedure will have to address the problem of proper plume removal with the ability to control dehydration. Cleaner LASIK outcomes will require an efficient plume evacuation system that not only reduces the incidence of beam masking and plume splatter onto the laser's lens, but also allows for improved control of dehydration during evacuation.

### Irrigation

Surgeons must perform irrigation of the corneal surface using sterile fluids multiple times during LASIK surgery. Irrigation is used to (1) wet and lubricate the cornea before keratotomy; (2) hydrate the tissues; (3) rinse laser and keratome generated micro-debris from the surgical zone before flap repositioning; and (4) facilitate re-floating the flap back into the original position.

Presently, the irrigation procedure uses various devices requiring extensive manipulations. Problems arise when excessive irrigation fluids backwash and collect forming a lake in the nasal or temporal canthal triangle and mix with the conjunctiva, lids, and fornix areas requiring the introduction and application of sponges. The pooling of fluids can be a contributing source of infectious and non-infectious contamination even after washing the surface with betadine and antibiotic solutions. Any back-washing of the pooled irrigation fluids into the stromal bed and flap increases the risk of

infectious/inflammatory complications. The exposed corneal stroma of both flap and bed absorb fluid readily, like a sponge.

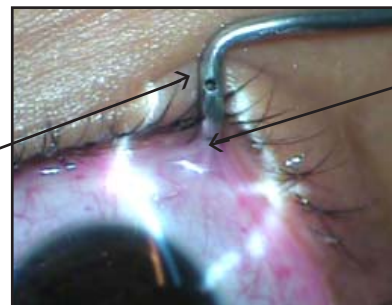To achieve a cleaner LASIK, the irrigation procedure requires less instrumentation and accompanying manipulations coupled with non-turbulent laminar sterile irrigation without backwash onto the surgical site.

### Aspiration

During LASIK surgery effective removal of irrigation and tissue fluids can reduce backwash of micro-debris, contaminants, and foreign material onto the exposed stromal bed and the corneal flap. How is aspiration of these invasive contaminants handled at present? In conventional LASIK practice, fluid is allowed to reach a level where it runs off the surgical field, if it has not been effectively removed by an aspirating lid speculum or absorbed by sponges (Figure 3). Karp et al<sup>9</sup> stated that it is necessary to remove pooling fluids by absorption or mechanical means to reduce the levels of fluid exposure in the surgical field in order to minimize infectious keratitis after surgery.

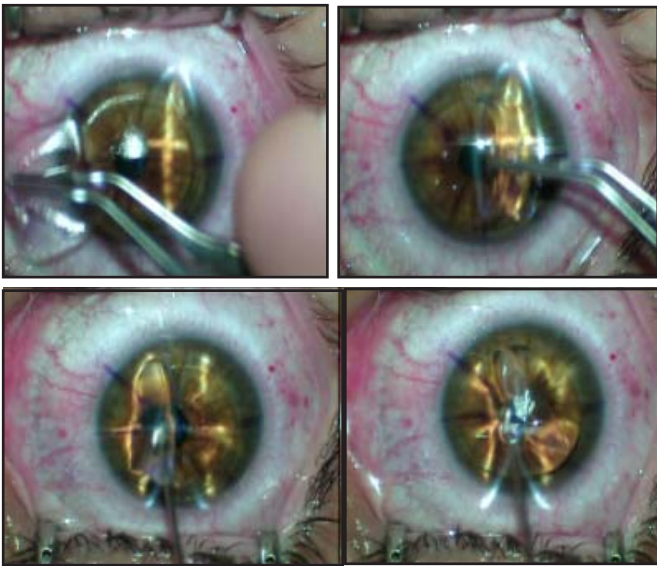
Surgical sponges help to reduce fluid pooling but are limited by their absorption capacity and retain and concentrate fluids in or near proximity to the surgical field. In addition, sponges tend to rough up the exposed stromal tissue. With respect to aspirating lid speculums,

Upper port of aspiration speculum is ineffectively positioned above surgical field.



Patient's conjunctiva sucked into port of aspiration speculum.

**Figure 4.** Example of lid speculum aspiration port plugged by conjunctiva. This contributes to increased contamination from pooling and fluid backwash during conventional LASIK.



**Figure 5.** Example of the use of forceps to grasp the flap and a cannula to manipulate the flap over onto the bed during conventional LASIK.

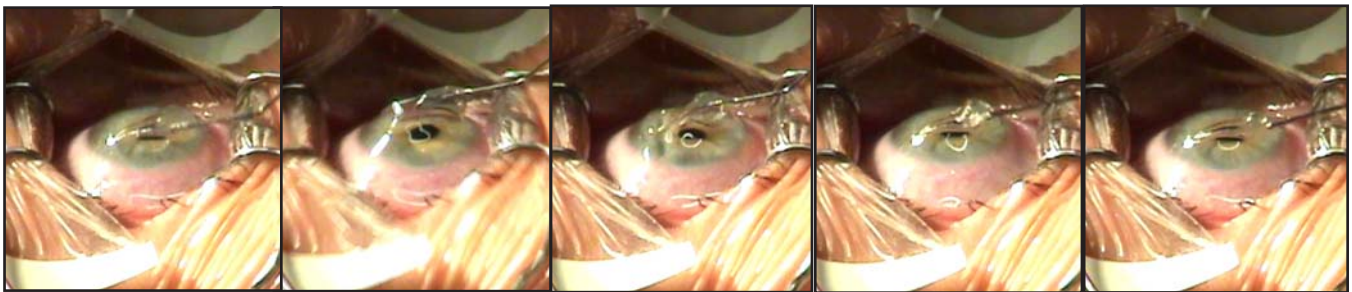
they have reduced efficiency in deep-set eyes and cannot prevent backwash of fluids onto the exposed stromal tissues. Figure 4 shows conjunctival tissue being sucked up into the port of an aspiration speculum obstructing and reducing the aspiration effectiveness.

A cleaner LASIK procedure mandates that these issues be resolved, perhaps by a better irrigation and aspiration design that minimizes flap manipulations and use of extraneous instrumentation while simultaneously guarding against backwash.

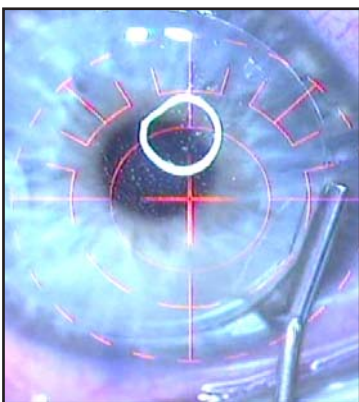
#### Flap repositioning and realignment

Ophthalmic surgeons Belda et al,<sup>10</sup> Pushker et al,<sup>2</sup> Rojas and Manche,<sup>11</sup> and Stewart<sup>12</sup> opine that reducing manipulation and exposure of the corneal bed and flap tissues to cul-de-sac fluids and lid margins

could decrease post-operative complications. Standard procedure is to reflect the flap over onto the flap bed by a series of flap manipulations using surgical forceps, spatulas, and/or cannulae. Figure 5 illustrates multiple maneuvers



**Figure 6.** Example of additional manipulations using a cannula introduced between the flap and flap bed. This is typical of conventional LASIK during re-floating to smooth out the flap folds.



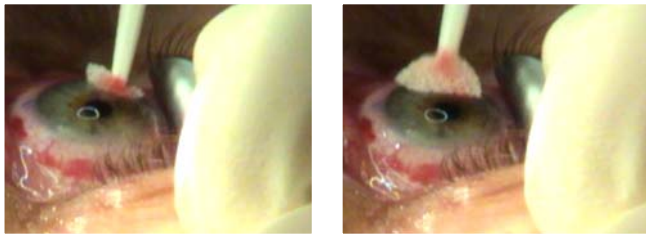
**Figure 7.** Because there is no surgical field containment in conventional LASIK, during re-floating debris may backwash and become trapped in the flap/bed interface.

using forceps and a cannula to reflect the flap over onto the stromal bed. After the flap has been reflected onto the bed using additional manipulations, an irrigation cannula connected to a manual squeeze bottle or syringe is inserted between the flap and its bed.

This added manipulation delivers uncontained irrigation fluid that floats the flap allowing the surgeon to smooth out and align the flap back into its original position (Figure 6).

Irrigation fluids add to the pooling and backwashing of surgical fluids and increase the time and manipulation needed to dry and fixate the flap. The fluids can pool and mix with the lid margins and lashes and backwash cellular debris into the flap bed interface where it becomes permanently trapped (Figure 7). Any material left in the interface has the potential to cause diffuse lamellar keratitis, infectious keratitis, and can contribute to epithelial undergrowth.<sup>13-15</sup>

We need to find a way to reduce the number of flap manipulations in order to improve flap repositioning and realignment. A means has to be designed to keep



**Figure 8.** A sponge repeatedly is used in an uncontained environment to squeegee the flap and corneal tissues.

the flap out of the fluid pools, eliminate the fluid, or both so that a cleaner surgical field results in a cleaner LASIK procedure.

### Flap adherence

Following repositioning and alignment, the corneal flap must adhere uniformly to the corneal surface in order to reduce flap complications such as macro/micro striae and epithelial ingrowth. After flap replacement, the surgeon normally observes the flap from 3 to 5 minutes allowing the flap to adhere. Some surgeons may use a surgical sponge to dry the gutter or squeegee the flap in an attempt to shorten the time to adherence. This action may shorten the time, but a sponge is rough. Its excessive use can create or extend abrasions along the flap surface and margins which may contribute to flap-related complications. Because the surgical field in conventional LASIK is uncontained, the sponge may absorb surgical fluids and cellular debris. This flotsam inadvertently can be painted over the flap tissues, or

a micro-abrasion from the keratotomy can be made worse with repeated sponge use during squeezing the flap down and out as illustrated in Figure 8.

Perez<sup>16</sup> demonstrated that airflow across the repositioned flap accelerates flap adhesion and safely shortens the 3 to 5 minute adhesion wait time. This method also allows for flap drying in a uniform manner.

A cleaner LASIK procedure will have to improve the method of providing micro-filtered, sterile, laminar airflow to the realigned flap so that the stromal-to-stromal adherence can be safely accelerated, the flap dried in a uniform manner, and the use of surgical sponges minimized.

## CONCLUSIONS

Research of the scientific literature revealed the incidence of less than desired outcomes requiring a need for additional surgery ranged from 8.0 to 23%. In a retrospective study of LASIK performed on 431 eyes using the LAHayeSIK System the incidence of retreatment was less than one percent (Table).

The nine goals for cleaner LASIK surgery as described above have been achieved through the use of the LAHayeSIK™ System. The procedure is described in *Techniques in Ophthalmology* 2006; 4(1):12-18.

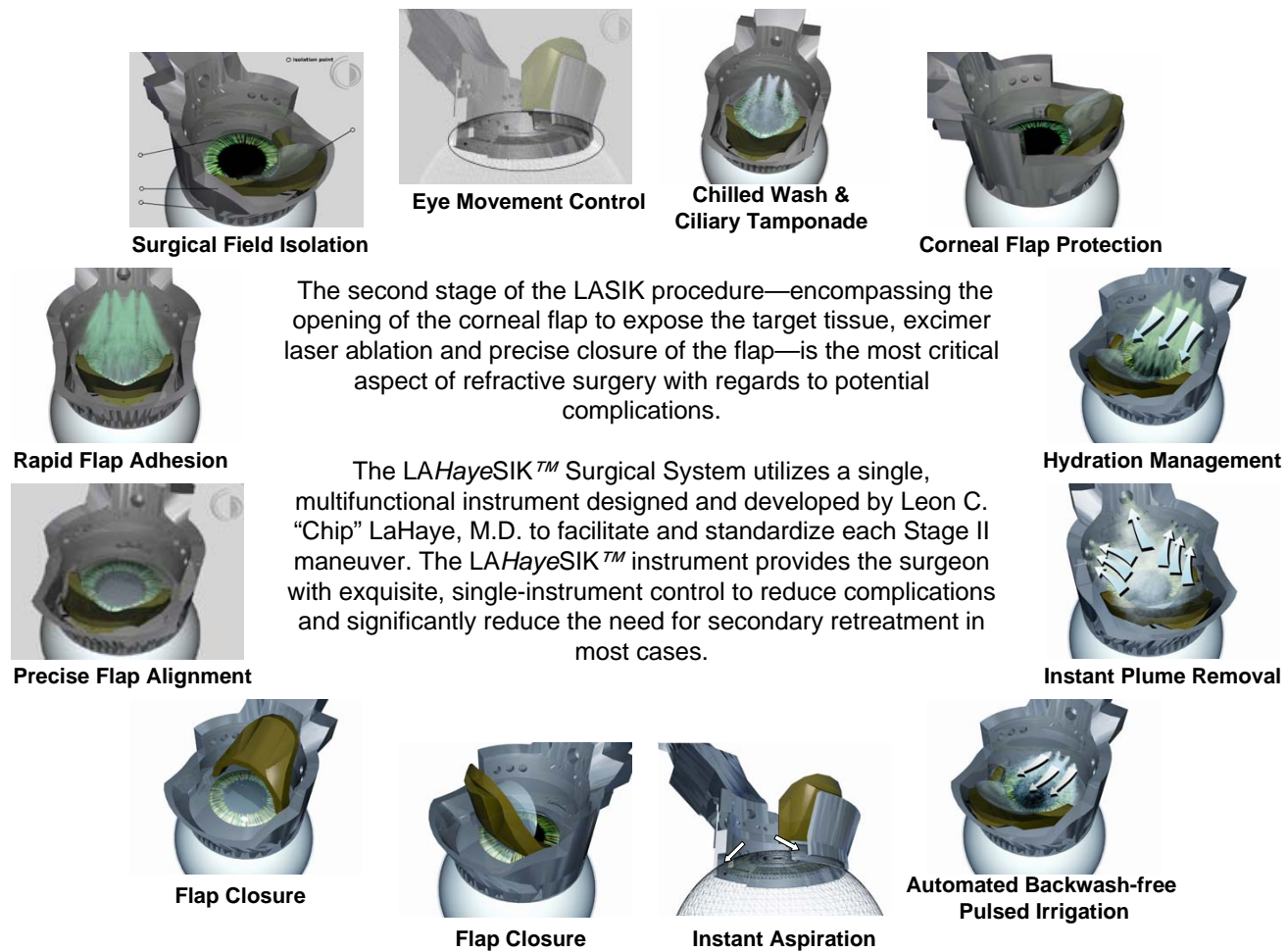
Over the past 10 years LASIK surgery has improved owing to advancements in excimer laser and keratome technology. The only other avenue of substantial improvement has to come through the improvement of surgical methods and devices that reduce the majority of complications associated with laser refractive procedures (Figure 9).

## REFERENCES

- Buratto L, Brint SF. *Custom LASIK: Surgical Techniques and Complications*. Thorofare, NJ: Slack Inc; 2003:816 pp.
- Pushker N, Dada T, Sony P, et al. Microbial keratitis after laser in situ keratomileusis. *J Refract Surg* 2002; 18:280-286.
- Dougherty PJ, Wellish KL, Maloney RK. Excimer laser ablation rate and corneal hydration. *Am. J. Ophthalmol* 1994; 118:169-176.
- Oshika T, Klyce SD, Smolek MK, et al. Corneal hydration and central islands after excimer laser photorefractive keratectomy. *J Cataract Refract Surg* 1998; 14:1575-1580.
- Zhigilei LV. Dynamics of the plume formation and parameters of the ejected clusters in short-pulse laser ablation. *Appl Phys A* 2003; 76:339-350.
- Yingling YG, Zhigilei LV, Garrison BJ. Laser ablation of biocomponents systems: a probe of molecular ejection mechanisms. *Appl Phys Letters* 2002; 78:1631-1633.
- Dell S. New system permits safe, more effective plume evacuation. *Ophthalmol Times* 2003; 28:48.
- Piechocki M. Lack of data complicates concerns over LASIK surgical smoke. *Ocular Surg News* 2002; 20:64-67.
- Karp C, Tuli SS, Yoo SH, et al. Infectious keratitis after LASIK. *Ophthalmol* 2003; 110:503-510.
- Belda J, Artola A, Also J. Diffuse lamellar keratitis 6 months after uneventful laser in situ keratomileusis. *J Refract Surg* 2003; 19:70-71.

**Table.** LAHayeSIK™ results in 431 eyes.

Reasons for Retirements	Incidence	
	Traditional	LAHayeSIK™
▶ Under / Overcorrection	4.9%-15.0%	0.5%
▶ DLK	1.0%-4.0%	0.0%
▶ Epithelial Ingrowth	0.9%-2.2%	0.0%
▶ Flap Striae	1.2%	0.2%
▶ Decentered Ablation	< 1.0%	0.0%
▶ Off-Axis Ablation	1.0%	0.0%
▶ Infectious Keratitis	0.1%-0.3%	0.0%
▶ Haze/Stromal Scarring	-----	0.0%
Retreatment Totals: Min / Max	<b>8.0%-23.0%</b>	<b>0.7%</b>



**Figure 9.** Second stage of the LASIK procedure utilizing LAHayeSIK™ Surgical System.

11. Rojas M, Manche E. Early diagnosis, treatment essential when facing DLK. *Ophthalmol Times* 2001; 26:5-8.
12. Stewart P. Sands of the Sahara. In: Linebarger, Hardten, Linstrom (editors). *LASIK: Surgical Techniques and Complications*, 2nd edition. Thorofare, NJ: Slack Inc; 2xxx:597-598.
13. Haddril M. Prolonged sterilization may be needed for killing endotoxins. *EyeWorld* 2002; 7:31-32.
14. Lipner M. The opportunists: infectious organisms cozying up to LASIK. *EyeWorld* 2002; 7:22-27.
15. Naoumidi I, Papadaki T, Zacharopoulos I, et al. Epithelial ingrowth after laser in situ keratomileusis. *Arch Ophthalmol* 2003; 121:950-955.
16. Perez E. Factors affecting corneal stroma-to-stroma adhesion. *J Refract Surg* 1998; 14:460-462.

**Dr. LaHaye, II** is the medical director of LaHaye Total Eye Care in Lafayette, Louisiana. His e-mail is [ifxiis@lahayesight.com](mailto:ifxiis@lahayesight.com). **Dr. Rieke** is professor of petroleum engineering at the University of Louisiana at Lafayette. **Dr. Farshad** is a Chevron-endowed research professor in the department of chemical engineering at the University of Louisiana at Lafayette. For more information on LAHayeSIK™ visit <http://www.lahayesik.com>.